

Received: 2017.03.13  
Accepted: 2017.04.27  
Published: 2017.07.13

ISSN 1941-5923  
© Am J Case Rep, 2017; 18: 790-793  
DOI: 10.12659/AJCR.904295

## Congestive Heart Failure with Preserved Ejection Fraction in a Patient with Light Chain (AL) Amyloidosis and Multiple Myeloma

Authors' Contribution:  
Study Design A  
Data Collection B  
Statistical Analysis C  
Data Interpretation D  
Manuscript Preparation E  
Literature Search F  
Funds Collection G

ABCDEF 1 **Edgar Francisco Carrizales-Sepúlveda\***  
ABCDEF 2 **Alejandro Ordáz-Farías\***  
BCF 1 **Raymundo Vera-Pineda**  
ACD 2 **Mario Alberto Benavides-González**  
ACD 2 **Ramiro Flores-Ramírez**

1 Department of Internal Medicine, University Hospital, Nuevo León Autonomous University, Monterrey, Nuevo León, México  
2 Echocardiography Laboratory, Cardiology Service, University Hospital, Nuevo León Autonomous University, Monterrey, Nuevo León, México

\* These authors contributed equally to this work

**Corresponding Author:** Alejandro Ordáz-Farías, e-mail: [ordaz7@gmail.com](mailto:ordaz7@gmail.com)  
**Conflict of interest:** None declared

**Patient:** Male, 53  
**Final Diagnosis:** Cardiac amyloidosis  
**Symptoms:** Dyspnea • chest pain • swelling  
**Medication:** —  
**Clinical Procedure:** Diagnostic approach  
**Specialty:** Cardiology

**Objective:** Challenging differential diagnosis





**Background:** Amyloidosis is characterized by tissue deposition of insoluble fibrillar proteins and it affects almost every organ; there are many types and the heart can be affected in all of them.

**Case Report:** Our report describes a middle-aged man who presented to the Emergency Department with congestive heart failure. Clinical, electrocardiographic, and echocardiographic findings suggested the presence of an infiltrative disease, so an abdominal fat tissue biopsy was performed. A final diagnosis of systemic amyloidosis with heart involvement was made.

**Conclusions:** This case highlights the importance of combining clinical, electrocardiographic, and echocardiographic information in the diagnosis of complex diseases like amyloidosis with heart involvement.

**MeSH Keywords:** Amyloidosis • Echocardiography • Heart Failure • Multiple Myeloma

**Full-text PDF:** <http://www.amjcaserep.com/abstract/index/idArt/904295>

 1345  —  2  12



## Background

The term amyloidosis describes a group of diseases in which extracellular tissue deposition of insoluble fibrillar protein occurs; it affects almost every tissue in the body and results in infiltration and swelling that leads to progressive loss of function of the involved organ [1]. The disease can be referred as localized (limited to 1 organ) or systemic (multiple organ involvement). There are many types of systemic amyloidosis and the heart can be affected in virtually all of them; however, only primary, hereditary, and senile amyloidosis cause clinically significant heart disease that can present as congestive heart failure, angina, and arrhythmias [2]. We present a case with systemic amyloidosis involving the heart, presenting on admission with congestive heart failure with preserved ejection fraction.

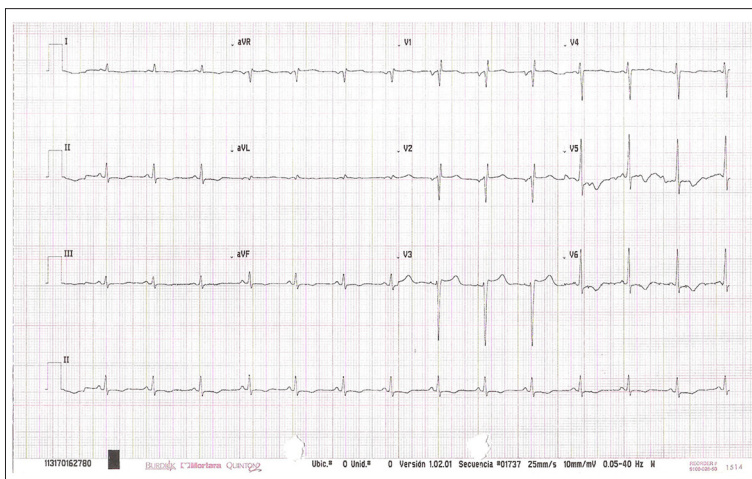
## Case Report

A 53-year-old man presented to the Emergency Department with minimal-effort dyspnea, orthopnea, and bilateral lower-extremity edema. He had a prior history of bilateral carpal tunnel syndrome that was treated by a neurologist and had improved; his medical record was otherwise unremarkable and he had no history of familiar relevant diseases. He reported that he used to run every day at least 3 to 5 kilometers. Symptoms began 15 months before admission with an episode of chest pain during exertion that subsided with rest; after that, he noted shortness of breath that appeared during effort and that progressed until it was present even at rest. He also reported 4 episodes of syncope during the previous 7 months. On physical examination, the patient was pale and diaphoretic. Blood pressure was 90/60 mmHg in both arms, in standing and supine position. Heart rate was 108 beats per min, respiratory rate was 22 breaths per min, with 92% oxygen saturation on room air. Cardiovascular examination revealed elevated jugular venous pressure, an S4 sound, and an apical systolic murmur.

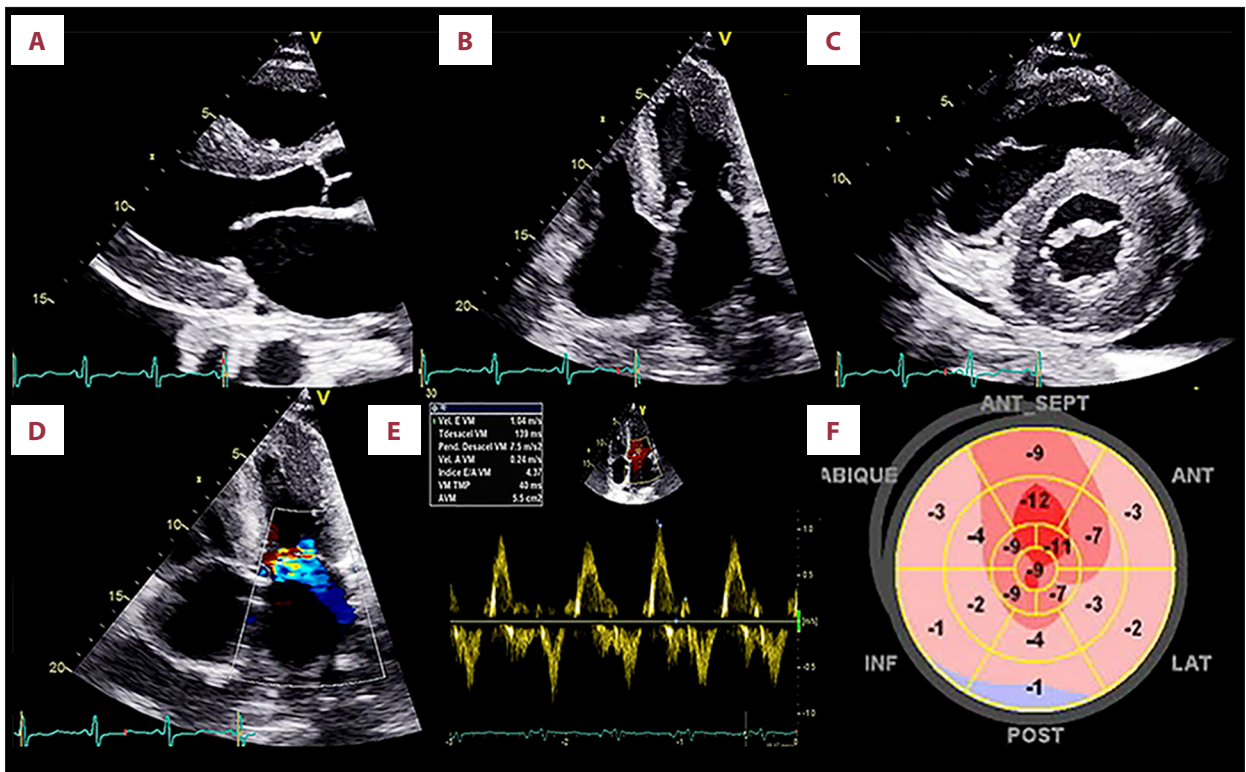
During lung auscultation, bilateral basal rales and a bilateral pleural effusion syndrome were noted. There was bilateral lower-extremity edema that extended to the knees.

A chest x-ray was obtained and showed vascular redistribution and bilateral pleural effusion. An electrocardiogram (ECG) showed a sinus rhythm at a rate of 84 beats per min, low voltage in limb leads, and poor R wave progression from V1 to V4 (Figure 1). A transthoracic 2D echocardiogram was performed (Figure 2), showing a myocardium with a “granular sparkling” appearance, a small pericardial effusion, bi-ventricular hypertrophy with an interventricular septal thickness of 2.1 cm, a left ventricular (LV) posterior wall thickness of 2 cm, and LV mass of 278.87 g, with an indexed LV mass of 141.56 g/m<sup>2</sup> and a reduced left ventricular cavity. There was bi-atrial enlargement, mild pulmonary regurgitation, and moderate mitral and tricuspid regurgitation. Systolic function was preserved with a left ventricular ejection fraction (LVEF) of 52% and there was severe diastolic dysfunction with an E wave velocity of 104 cm/s, E' wave velocity of 5 cm/s, A wave velocity of 24 cm/s, E/A ratio of 4.37, E/E' ratio of 22.28, and a deceleration time of 139 ms. Right ventricular systolic function was deteriorated, with a tricuspid annular plane systolic excursion (TAPSE) of 12 mm, and there was moderate pulmonary hypertension with a pulmonary artery systolic pressure of 54 mmHg. Myocardial strain was assessed using speckle-tracking technique, showing global dysfunction, predominately of basal segments with some sparing of medial and apical segments.

Due to the data obtained, amyloidosis was suspected and an abdominal fat tissue biopsy was performed. Congo Red and Thioflavine staining were positive for amyloid deposits. Serum protein electrophoresis and immunofixation electrophoresis revealed a monoclonal spike visible in the beta region, with immunoglobulin A (IgA) of 19.46 g/L and free lambda ( $\lambda$ ) light chains. A bone marrow biopsy was performed, showing 15% clonal plasma cells. A diagnosis of light chain multiple myeloma



**Figure 1.** Electrocardiogram. Sinus rhythm with low-voltage QRS complexes in limb leads, with intraventricular conduction disturbance.



**Figure 2.** (A) Parasternal long axis, (B) apical-4-chamber, (C) parasternal short axis with myocardial granular appearance, and generalized hypertrophy with bi-atrial enlargement. (D) Doppler color in apical 4-chamber view shows mild-to-moderate mitral regurgitation. (E) Pulsed-wave Doppler imaging of mitral inflow with restrictive filling (increased E velocity, reduced A velocity, and an E/A ratio of 4.3) (F) Global longitudinal strain (GLS) with speckle-tracking in the bullseye plot with  $-6\%$ . Note the low LS in the basal and mid-ventricular segments, with relative apical sparing.

(MM) with systemic AL amyloidosis involving the heart was made. After stabilization of acute complaints, the patient was referred to the hematology service of our institution and began chemotherapy for his MM.

## Discussion

The heart is one of the most frequently affected organs in amyloidosis. The spectrum of presentation can range from asymptomatic ventricular dysfunction to congestive heart failure, with preserved or reduced ejection fraction [3]. AL amyloidosis is the most common type and cardiac involvement can be present in almost 60% of these patients [2]. Because other manifestations of the disease are often nonspecific, a high index of suspicion is needed based on clinical, electrocardiographic, and imaging techniques to establish a correct diagnosis. Nearly all patients with cardiac amyloidosis (CA) present with electrical disturbances. One of the largest studies reported on electrocardiographic findings in 127 patients, finding that the 2 most frequent abnormalities are low QRS voltage in limb and precordial leads and a pseudoinfarction pattern, and that these abnormalities are seen in almost 50% of patients [4].

Echocardiography is one of the noninvasive methods of choice for the diagnosis of cardiac involvement. The main echocardiographic findings include “sparkling” or “snowstorm” appearance of the myocardium, increased wall thickness of the left and right ventricle, normal or small left ventricular cavity, bi-atrial dilatation, increased interatrial septal thickness, thickening of the valves with mild regurgitation, small pericardial effusion, and atrial thrombi. Ventricular function is characterized by a preserved LVEF  $>50\%$ , at least in the early stages of the disease. Mild-to-moderate forms of diastolic dysfunction are seen early in the disease progression and a severe restrictive pattern with an E/A  $>2$ , increase E/E', and a small A wave due to atrial dysfunction in the later stages. Right ventricular systolic and diastolic functions can also be affected in CA [2,3,5]. New echocardiographic methods have been used to assess the ventricular function in CA, and a study evaluating cardiac function with 2D speckle-tracking imaging showed that the amyloid heart is characterized by reduced basal strain and regional variations in longitudinal strain from base to apex, and that a relative “apical sparing” pattern is both sensitive and specific to identify and differentiate CA from other causes of LV hypertrophy [6].

Although endomyocardial biopsy is still the criterion standard for diagnosing CA, it is not indicated in all patients and, as we did with our patient, combining different methods can help achieve the correct diagnosis. Criteria for cardiac involvement were defined in the 2005 consensus for amyloid and amyloidosis [7]. CA amyloidosis is defined as a LV mean wall thickness of >12 mm in echocardiography with no other cardiac cause, and histological proof of amyloid deposition with a biopsy of an affected organ or an alternative site, like abdominal fat tissue [7]. Combining electrocardiography and echocardiography for CA diagnosis has also proven useful. Because inherent amyloid deposits in the extracellular matrix of the myocardium, wall thickness increases giving a false impression of ventricular hypertrophy; however, patients rarely meet criteria for LV hypertrophy in the ECG, so the discrepancy between low ECG voltages and increased ventricular mass on the echocardiogram has shown to be a cardinal feature of CA and has a sensitivity of 72% and a specificity of 91% for diagnosis [8].

It is important to differentiate the heart involvement from AL, as well as senile and hereditary amyloidosis, since these have different treatments and prognoses. AL amyloidosis has the worst prognosis, with a median survival of 5 months and 2.3

years in patients with and without cardiac involvement, respectively [9]. Some epidemiological, clinical, and echocardiographic characteristic appear to be useful in distinguishing among the main types of amyloidosis that affect the heart [10]; however, identification of light chains and DNA mutations is crucial to adequately distinguish between these.

## Conclusions

We demonstrated the importance of considering CA as an unusual cause of congestive heart failure with preserved ejection fraction in order to make a correct and early diagnosis. It is important to consider amyloid deposits as an unusual cause of heart failure with preserved ejection fraction [11,12], as well as to combine different diagnostic methods to characterize the disease. In our case, we had no magnetic resonance imaging or endomyocardial biopsy to prove the diagnosis, but using clinical, ECG and echocardiographic findings allowed us to make the right diagnosis.

## Conflict of interest

The authors have no conflicts of interest to disclose.

## References:

1. Hazenberg BP: Amyloidosis: A clinical overview. *Rheum Dis Clin North Am*, 2013; 39(2): 323–45
2. Shah KB, Inoue Y, Mehra MR: Amyloidosis and the heart: A comprehensive review. *Arch Intern Med*, 2006; 166(17): 1805–13
3. Banyersad SM, Moon JC, Whelan C et al: Updates in cardiac amyloidosis: A review. *J Am Heart Assoc*, 2012; 1(2): e000364
4. Murtagh B, Hammill SC, Gertz MA et al: Electrocardiographic findings in primary systemic amyloidosis and biopsy-proven cardiac involvement. *Am J Cardiol*, 2005; 95(4): 535–37
5. Mohty D, Damy T, Cosnay P et al: Cardiac amyloidosis: Updates in diagnosis and management. *Arch Cardiovasc Dis*, 2013; 106(10): 528–40
6. Phelan D, Collier P, Thavendiranathan P et al: Relative apical sparing of longitudinal strain using two-dimensional speckle-tracking echocardiography is both sensitive and specific for the diagnosis of cardiac amyloidosis. *Heart*, 2012; 98(19): 1442–48
7. Gertz MA, Comenzo R, Falk RH et al: Definition of organ involvement and treatment response in immunoglobulin light chain amyloidosis (AL): A consensus opinion from the 10<sup>th</sup> International Symposium on Amyloid and Amyloidosis, Tours, France, 18–22 April 2004. *Am J Hematol*, 2005; 79(4): 319–28
8. Rahman JE, Helou EF, Gelzer-Bell R et al: Noninvasive diagnosis of biopsy-proven cardiac amyloidosis. *J Am Coll Cardiol*, 2004; 43(3): 410–15
9. Kapoor P, Thenappan T, Singh E et al: Cardiac amyloidosis: A practical approach to diagnosis and management. *Am J Med*, 2011; 124(11): 1006–15
10. Rapezzi C, Merlini G, Quarta CC et al: Systemic cardiac amyloidosis: Disease profiles and clinical courses of the 3 main types. *Circulation*, 2009; 120(13): 1203–12
11. Nojima Y, Ihara M, Kurimoto T, Nanto S: Amyloid light-chain amyloidosis manifesting as heart failure with preserved ejection fraction in a patient with hyper-immunoglobulin E-emia. *Am J Case Rep*, 2016; 17: 235–40
12. Gonzalez-Lopez E, Gallego-Delgado M, Guzzo-Merello G et al: Wild-type transthyretin amyloidosis as a cause of heart failure with preserved ejection fraction. *Eur Heart J*, 2015; 36(38): 2585–94